

# **BILATERAL EFFECTS OF UNILATERAL THALAMIC DEEP BRAIN STIMULATION: A CASE REPORT**

*(Brief report)*

*Norbert Kovacs<sup>1\*</sup>, Endre Pal<sup>1</sup>, Hajnalka Merkli<sup>1</sup>, Lorant Kellenyi<sup>1</sup>, Ferenc Nagy<sup>1</sup>,  
Jozsef Janszky<sup>1</sup>, Istvan Balas<sup>2</sup>*

*<sup>1</sup>Department of Neurology, University of Pecs, Pecs, Hungary*

*<sup>2</sup>Department of Neurosurgery, University of Pecs, Pecs, Hungary*

*This is a preprint of an [article](#) published in  
[Movement Disorders](#). 2008 23(2):276-279  
Copyright: The Movement Disorder Society*

**Correspondence to:**

Dr. Norbert Kovacs

University of Pecs

Department of Neurology

H-7623, Pecs, Ret utca 2,

Tel: +36 70 2221178

Fax: +36 72 535911

Email: norbert.kovacs@aok.pte.hu

**Word count for text: 1376**

**Running title:** Bilateral effects of unilateral Vim DBS

## ABSTRACT

A recent study has proved that unilateral deep brain stimulation (DBS) of the subthalamic nucleus has bilateral effects. However, it is still unclear whether unilateral ventral intermediate thalamic nucleus DBS exerts exclusively contralateral or bilateral effects on tremor. Previous studies demonstrated a clinically irrelevant improvement on the nontarget side after thalamic stimulator implantation, which was considered to be solely a result of mechanical effects.

We report here the case of a 55-year-old woman in whom unilateral thalamic DBS can stop the disabling postural-kinetic tremor in both hands.

Simultaneous surface electromyography (sEMG), accelerometry and video recordings were obtained to evaluate the underlying mechanism. After the right Vim DBS was turned off, moderate rest tremor appeared in both hands accompanied by bilateral bursts on sEMG. Because right hand tremor cannot simply reflect the mechanical overflow of the left side, the bilateral improvement caused by right Vim DBS is probably due to an active tremor reduction in this particular case.

**Abbreviations:** DBS=deep brain stimulation; FTMTRS=Fahn-Tolosa-Marin Tremor Rating Scale; Vim=ventral intermediate thalamic nucleus.

**Keywords:** deep brain stimulation; mitochondrial encephalopathy, thalamotomy, tremor, ventral intermediate nucleus

## Introduction

Unilateral deep brain stimulation (DBS) of the ventral intermediate thalamic nucleus (Vim) is a technique widely used to relieve various types of tremor. However, the question of whether this technique exerts exclusively a unilateral or a bilateral tremor-reducing effect remains open. Using the Fahn-Tolosa-Marin Tremor Rating Scale (FTMTRS)<sup>1</sup>, Ondo, et al.<sup>2</sup> demonstrated a clinically slight, but statistically significant tremor reduction on the ipsilateral (nontarget) side. Nevertheless, they suspected exclusively mechanical causes rather than a direct CNS effect of the DBS.

## Methods

In a search for clinically bilateral effects, we reviewed all cases in which a unilateral Vim DBS had been implanted in the Departments of Neurology and Neurosurgery at the University of Pecs. Among the 16 cases involving thalamotomy and contralateral Vim stimulation (5 Parkinsonian tremor, 8 essential tremor, 2 multiple sclerosis, and 1 tremor associated with mitochondrial encephalomyopathy), we found only a single case where the unilateral thalamic DBS had clinically improved both the bilateral limb and head tremor. As the FTMTRS itself might be insufficient for a distinction between active and passive tremor reductions, we applied simultaneous surface electromyography (sEMG), accelerometry and video recording in order to evaluate the presence of an active tremor reduction on the nontarget side in this specific case.

### **The patient**

The 55-year-old woman suffers from tremor related to biopsy-proven mitochondrial encephalomyopathy. Her case was published previously with regard to patient history, tremor characteristics and surgical treatments<sup>3</sup>.

Briefly, at the age of 48, she experienced pharmaco-resistant bilateral, predominantly postural-kinetic limb and head tremor after several stroke-like episodes. The tremor affected the right side more seriously. The amplitude of the tremor was moderate at rest, higher in a postural situation and very serious under kinetic conditions. After a 1-year progression, the tremor had increased to such a level that she was no longer able to walk and take care of herself. Extensive examinations relating to the possibilities of Wilson's disease, Parkinson's disease, essential tremor, Holmes' tremor, psychogenic tremor and enhanced physiological tremor yielded negative results.

As the handicapping bilateral tremor was pharmaco-resistant, surgical treatment was offered. A left thalamotomy performed at the age of 50 resulted in a marked tremor reduction and 1 year later a DBS electrode was implanted into the right Vim<sup>3</sup>. With the stimulating parameters 0-C+, 130Hz, 60µs, 1.4V, permanent and pronounced tremor reduction was achieved<sup>3</sup>.

### **Tremor recording**

This investigation was performed in 2007, 4 years after the DBS implantation. Written informed consent was obtained for all the examinations described below and for the presentation of video recordings at scientific congresses or in scientific journals. Besides physical examination and the assessment of FTMTRS, we also applied simultaneous sEMG and accelerometry. Tremor was investigated in various positions: Rest tremor was examined while the patient was sitting in a chair with her forearms supported by the arms of the chair. The hands were able to dangle freely, and the patient was asked to relax her musculature.

To record postural tremor, one of the upper limbs was maintained against gravity, while the other was in a resting position. In the investigated arm, both goal-directed (finger-to-nose) and non-goal-directed (e.g. elbow extension and flexion) maneuvers were performed, while the other hand was also in resting position.

During each session, measurements lasting 2-10 minutes were made with calibrated accelerometers (ADXL-105, Analog Devices Inc., USA). For bipolar sEMG, Ag/AgCl electrodes were applied to the belly and the tendon of flexor and extensor forearm muscles. Signals were digitalized at a sampling rate of 1000Hz (Power1401, Cambridge Electronic Design Ltd., UK). The system was also capable of capturing a video signal synchronized with the electrophysiological recordings.

### **Data analysis**

The exact method of data processing and subsequent analyses was described previously. Technical artifacts were eliminated using Spike2 (version 6.03, Cambridge Electronic Design Ltd., UK). Subsequently, the data were filtered by applying a band-pass Butterworth digital filter (4<sup>th</sup> order; the passband was 0.7-35Hz for the accelerometric recordings and 50-350 Hz for the sEMG. Finally sEMG signal was rectified<sup>4</sup>. Three parameters were determined:

(1) The **frequency** of tremor was determined by analyzing autocorrelation curve<sup>5</sup>.

(2) The **intensity of tremor** was considered as the area under the power-spectrum in the range of 3-15Hz<sup>6,7</sup>.

(2) The **presence or absence of tremor-related bursts** on the sEMG signal was determined by both visual and cross-correlation analysis between the accelerometry and sEMG.

For qualitative analysis, the electrophysiological data and the video recording were investigated simultaneously, similarly to the video-EEG technique used in epilepsy monitoring.

### **Results**

If the **DBS was on**, no tremor could be detected visually in any of the examined positions, while the frequency of rest and postural tremors was relatively high (right: 8.12 Hz, left: 7.96 Hz). Tremor-related burst activity did not appear in the sEMG recordings.

After the **stimulator was turned off**, however, bilateral limb tremor and midline head tremor appeared on both sides (Figure, video). In the resting condition, the frequencies on the two sides were slightly different (right: 5.41Hz vs. left: 5.22Hz) and this difference increased when the right kinetic condition was considered (right: 6.29Hz vs. left: 5.28Hz). Furthermore, the intensity of right kinetic tremor was also much higher than that of left (1268 and 889 milli-g<sup>2</sup>, respectively). Finally, switching on the DBS abolished the bilateral tremor again.

## Discussion

The recent paper by Chung et al. on the bilateral effects of unilateral subthalamic nucleus DBS described an approximately 20% reduction in the UPDRS part III ipsilateral subscores<sup>8</sup>. Their result inspired us to test whether unilateral Vim DBS might have a bilateral tremor-reducing effect. A review of all of our cases, revealed only a single instance where unilateral thalamic stimulation after contralateral thalamotomy apparently caused clinically pronounced bilateral effects.

The electrophysiological examinations in this unique case indicated that the unilateral DBS definitely reduced the bilateral limb and head tremor:

1. After the right Vim DBS was turned off, moderate rest tremor appeared in both hands and the head. It might be hypothesized that the right-sided rest tremor could be a result of passive, mechanical effects of the left hand tremor, but the bursting of the right forearm muscles contradicts this.
2. The frequency of the right hand tremor was almost 1Hz higher in the right kinetic condition.
3. While the right hand was carrying out the finger-to-nose test and the left hand was in the resting position, the intentional tremor on the nontarget (right) side had a much higher intensity than the that on target side. Similarly during writing and spiral-drawing with the right hand, the right kinetic tremor was more pronounced than the left rest tremor.

Consequently, these right kinetic tremors cannot simply reflect the mechanical overflow of the left side.

4. When the stimulator was turned off, head tremor also developed. Previous studies have clearly demonstrated that bilateral thalamic stimulation is usually required to achieve the most consistent improvement in this symptom<sup>9, 10</sup>.
5. Other previous studies have revealed that Vim DBS increases the tremor frequency<sup>5, 6</sup>. In our case, when the right Vim DBS was switched on, the frequencies of both hands increased.

The physical examination and the electrophysiological data suggest active CNS oscillator(s) behind the right hand tremor, which can be inhibited by the right Vim DBS; the unilateral Vim stimulation therefore inducing bilateral effects. We cannot explain the exact mechanism underlying this phenomenon, and why it is manifested in only one subject and not in our other 15 patients with unilateral thalamotomy and contralateral Vim DBS.

We can merely speculate that the mechanism underlying this phenomenon may be disease-specific (e.g. mitochondrial disorder) in our patient. Alternatively, it may reflect an individual anatomical variation of the interconnections between the two hemispheres affected by the previous thalamotomy or may be a result of a combination of these mechanisms. The absence of similar phenomenon in the 15 other cases and the relatively low voltage level (1.4V) used for stimulation may suggest the presence of an individual neuroanatomical constellation. For a better understanding of the bilateral effect of unilateral DBS, further investigations (e.g. functional neuroimaging) may have been required. Functional MRI, however, cannot be performed for technical reasons<sup>11</sup> and the patient refused other neuroimaging methods involving the use of radiotracers (e.g. SPECT and PET).

## Acknowledgements

Present study was supported by OTKA T043005 Hungarian State Research Fund. We would also acknowledge David Durham, a native English speaker, for stylistic help.

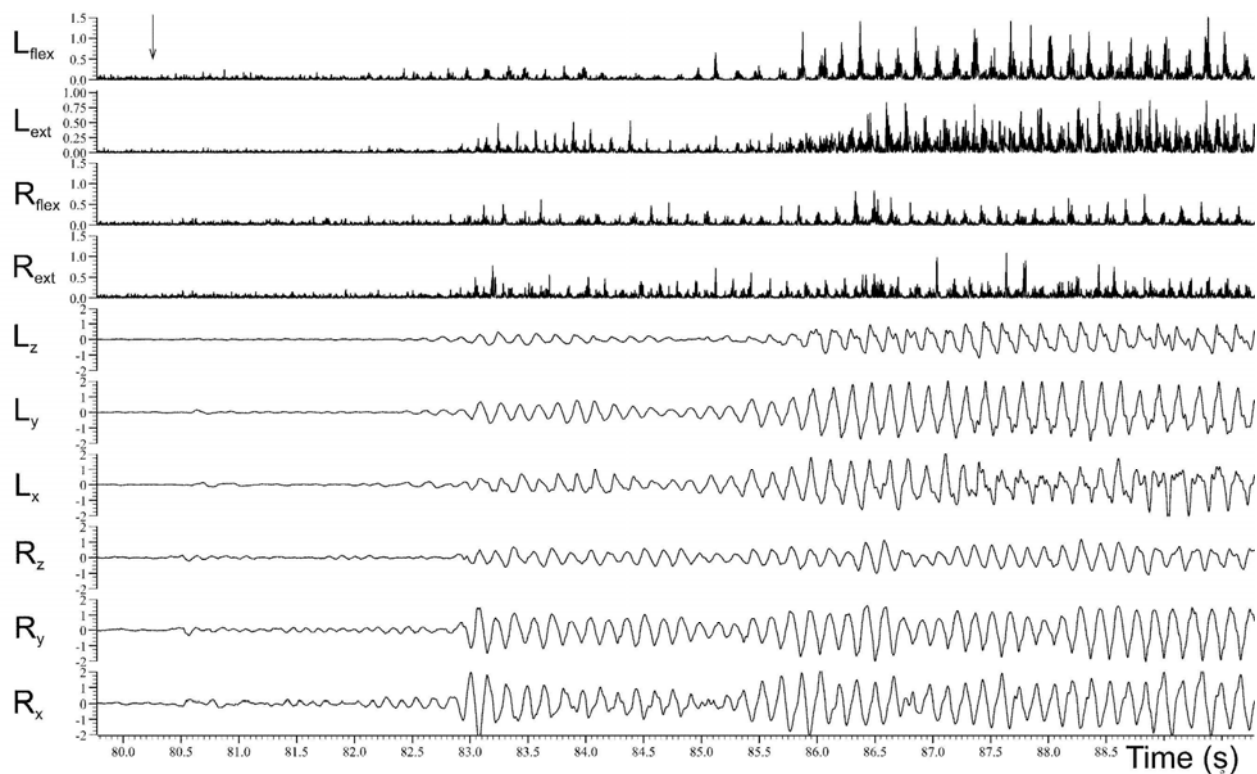
## References

1. Fahn S, Tolosa E, Marin C. Clinical Rating Scale for Tremor. In: Jankovic J, Tolosa E, eds. *Parkinson's disease and movement disorders*. Baltimore, MD: Williams and Wilkins, 1998:225-234.
2. Ondo W, Dat Vuong K, Almaguer M, Jankovic J, Simpson RK. Thalamic deep brain stimulation: effects on the nontarget limbs. *Mov Disord* 2001;16(6):1137-1142.
3. Kovacs N, Pal E, Balas I, Janszky J, Nagy F, Merkli H. Neurosurgical treatment of tremor in mitochondrial encephalopathy. *Mov Disord* 2006;21(12):2227-2230.
4. Raethjen J, Lauk M, Koster B, et al. Tremor analysis in two normal cohorts. *Clin Neurophysiol* 2004;115(9):2151-2156.
5. Vaillancourt DE, Sturman MM, Verhagen Metman L, Bakay RA, Corcos DM. Deep brain stimulation of the VIM thalamic nucleus modifies several features of essential tremor. *Neurology* 2003;61(7):919-925.
6. Kovacs N, Balas I, Illes Z, et al. Uniform qualitative electrophysiological changes in postoperative rest tremor. *Mov Disord* 2006;21(3):318-324.
7. Kovacs N, Balas I, Illes Z, Kellenyi L, Nagy F. [The role of tremorometry in predicting the outcome of ablative surgeries]. *Ideggyogy Sz* 2006;59(11-12):438-440.
8. Chung SJ, Jeon SR, Kim SR, Sung YH, Lee MC. Bilateral effects of unilateral subthalamic nucleus deep brain stimulation in advanced Parkinson's disease. *Eur Neurol* 2006;56(2):127-132.

9. Putzke JD, Uitti RJ, Obwegeser AA, Wszolek ZK, Wharen RE. Bilateral thalamic deep brain stimulation: midline tremor control. *J Neurol Neurosurg Psychiatry* 2005;76(5):684-690.
10. Ondo W, Almaguer M, Jankovic J, Simpson RK. Thalamic deep brain stimulation: comparison between unilateral and bilateral placement. *Arch Neurol* 2001;58(2):218-222.
11. Kovacs N, Nagy F, Kover F, et al. Implanted deep brain stimulator and 1.0-Tesla magnetic resonance imaging. *J Magn Reson Imaging* 2006;24(6):1409-1412.

## Legends

**Figure.** A simultaneous accelerometric and surface EMG recording (sEMG) is presented. The right Vim DBS was turned off at 80.5s (marked with arrow). L=left, and R=right side. In the accelerometric recordings, the indices x, y, z indicates the 3 different planes. Flex and ext denote sEMG of flexor and extensor forearm muscles. One x-axis unit is equal with 1 gravity ( $9.8\text{m/s}^2$ )



## Video.

Segment 1. Right Vim DBS is turned on.

Segment 2. Turning off the DBS

Segment 3. Right Vim DBS is turned off.